

FAST

Focused Assessment with Sonography for Trauma



Ultrafest
MARIBOR

Created by: Matevž Privšek, MD, Una Mršič, Sara Nikolić, Jan Hansel, MD

Revised by: assist. Gregor Prosen, MD, emergency medicine specialist, FEBEM

Medical Faculty, University of Maribor, Taborska 8, SI2000- Maribor, Slovenia

Ultrafest is an original idea from UC Irvine, kindly shared and supported in good spirit of open-access educational materials.
Kind acknowledgements to dr. J C Fox and dr. C Fischetti for support in setting up Ultrafest Maribor chapter.



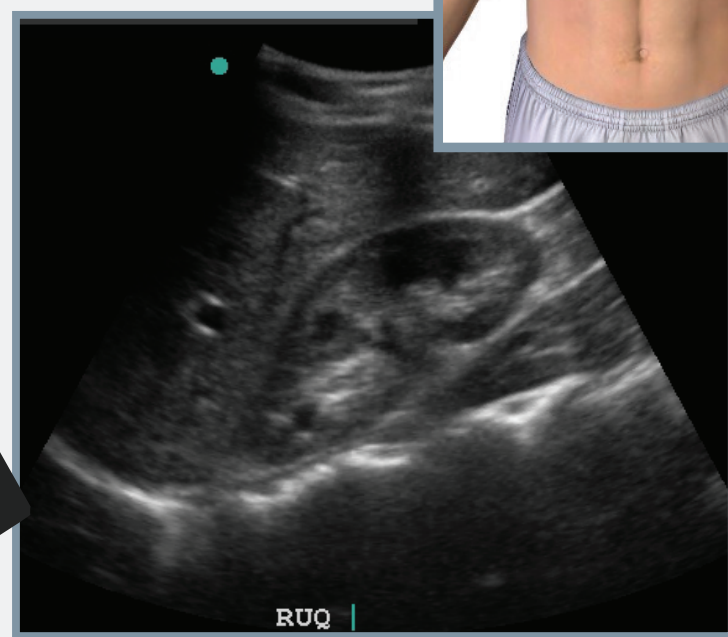
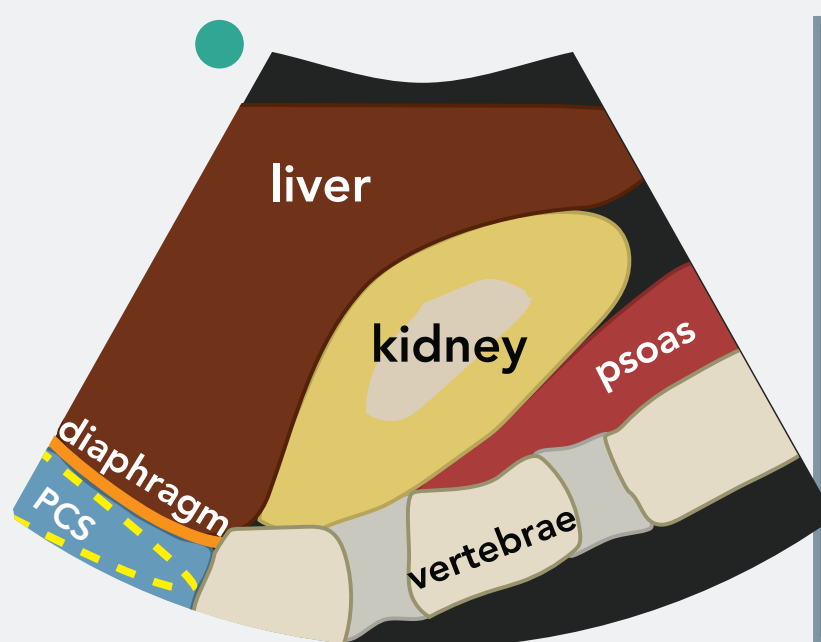
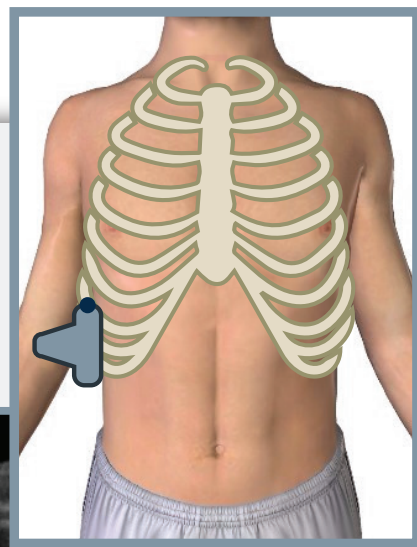
STATION GOALS

To assess the presence of free fluid in abdominal cavity and pericardial sac.

Probe: Convex array probe (5-3 MHz)

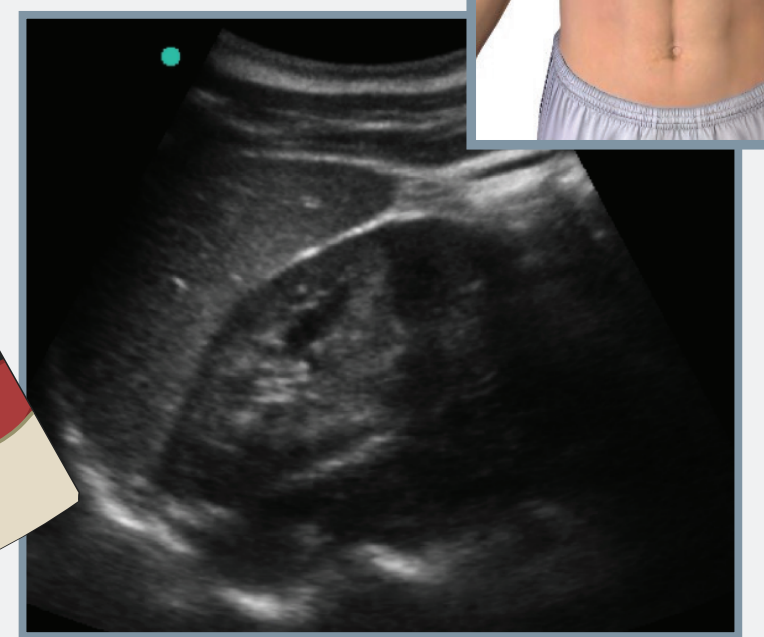
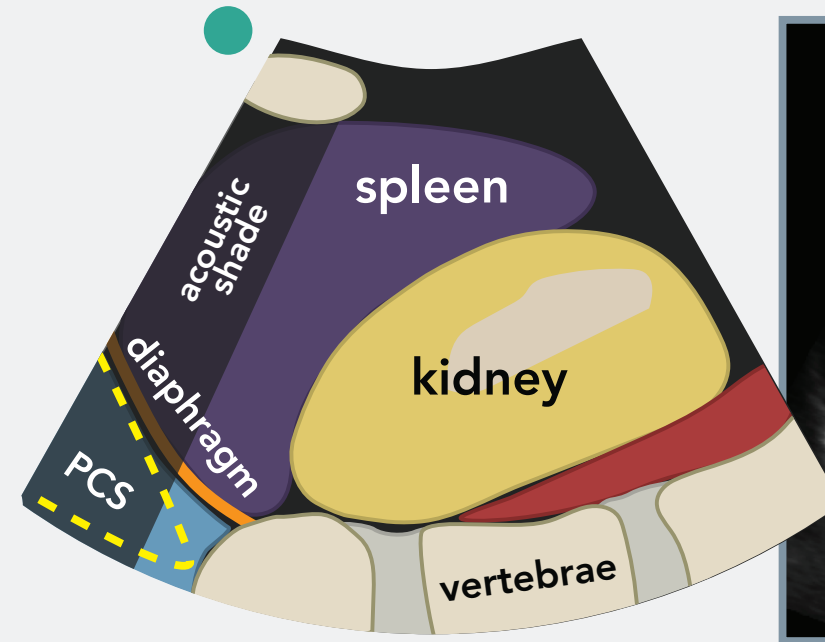
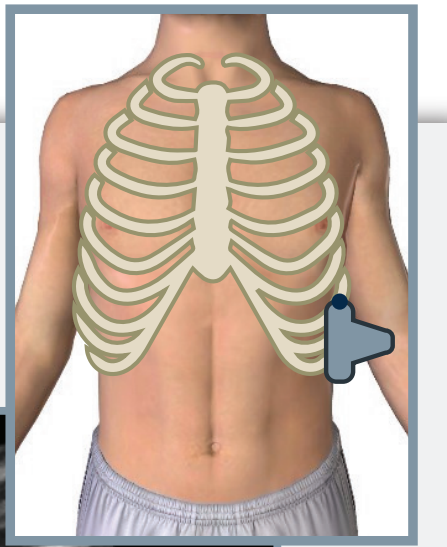
Patient body position: Supine

Right upper quadrant



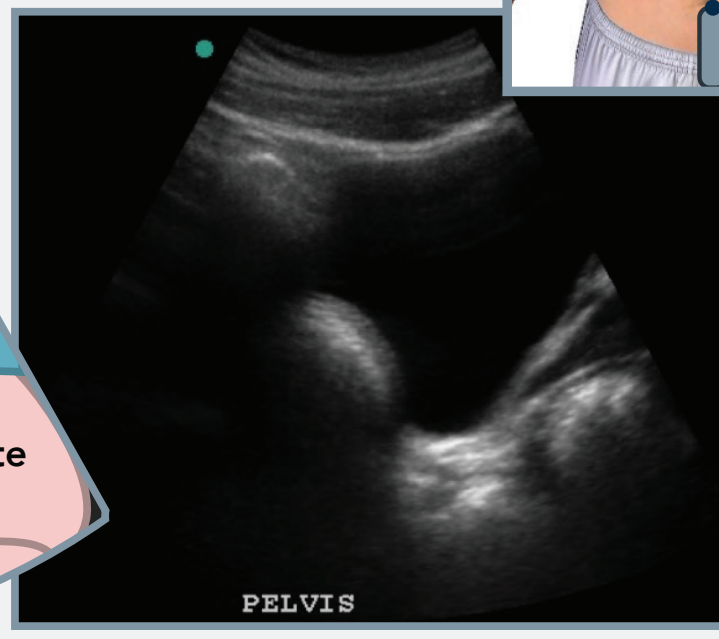
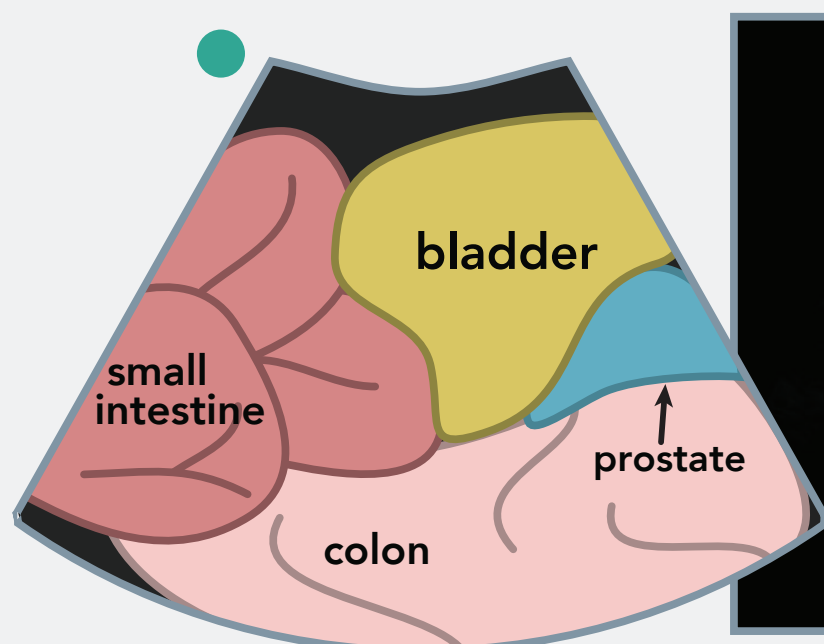
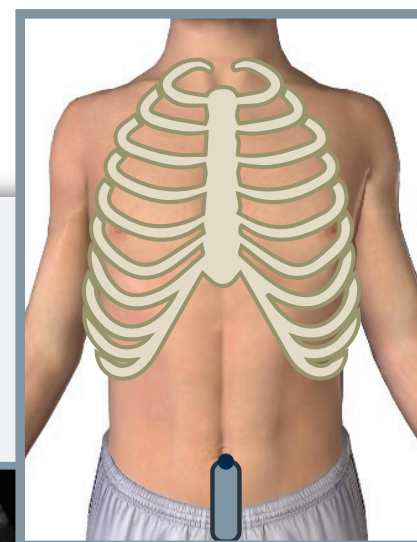PCS = phrenicocostal sinus

Left upper quadrant

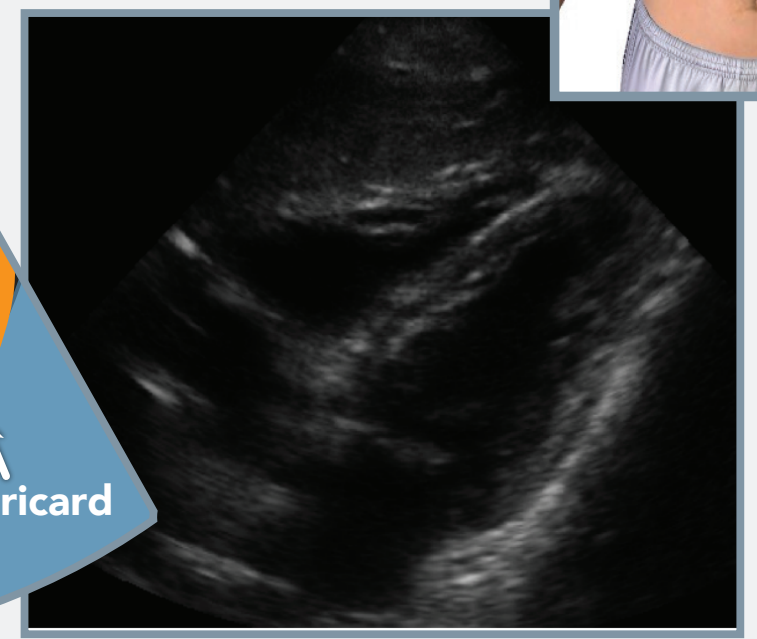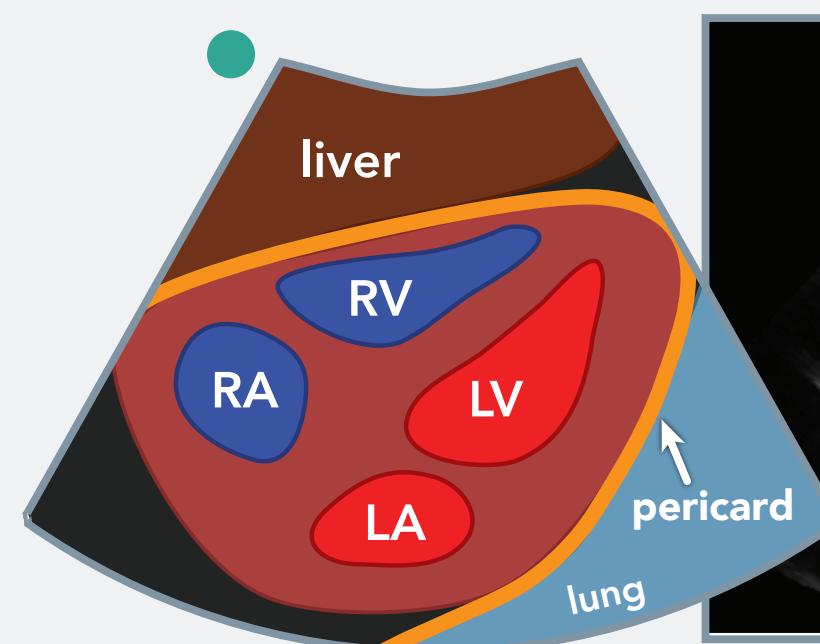
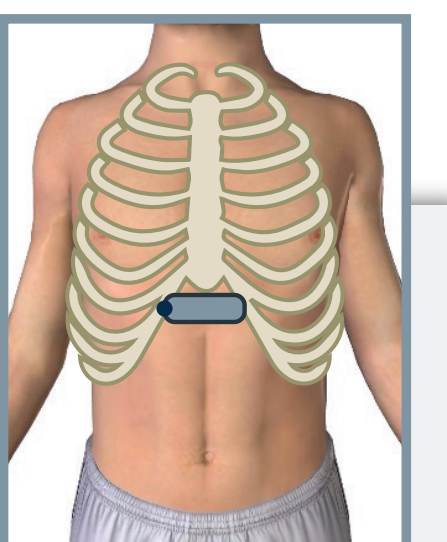


PCS = phrenicocostal sinus

Suprapubic view



Subcostal view



US TECHNIQUE

In all windows we examine the presence of free fluid which is seen as anechogeneous structure.

For better image of Morrison and perisplenic cavity we can help ourselves with the rotation of the probe parallel to intercostal space.

At subcostal view the heart can be seen clearer if the probe is held in a more horizontal position.

INTERESTING CLINICAL FACTS

43-20 % of patients shows no abnormalities in physical exam after the primary survey.

FAST exam has 99-86 % sensitivity and 99-90 % specificity for detecting the presence of free fluid.

The sensitivity of the FAST exam can be increased by fanning motion to acquire spatial 3D images.

FAST exam is positive already when a small zone of fluid is found in any of the views.